

# INDIRECT COMPUTED TOMOGRAPHIC LYMPHOGRAPHY FOR ILIOSACRAL LYMPHATIC MAPPING IN A COHORT OF DOGS WITH ANAL SAC GLAND ADENOCARCINOMA: TECHNIQUE DESCRIPTION

STEPHANIE A. MAJESKI, MICHELE A. STEFFEY, MARK FULLER, GERALDINE B. HUNT,  
PHILIPP D. MAYHEW, RACHEL E. POLLARD

Sentinel lymph node mapping can help to direct surgical oncologic staging and metastatic disease detection in patients with complex lymphatic pathways. We hypothesized that indirect computed tomographic lymphography (ICTL) with a water-soluble iodinated contrast agent would successfully map lymphatic pathways of the iliosacral lymphatic center in dogs with anal sac gland carcinoma, providing a potential preoperative method for iliosacral sentinel lymph node identification in dogs. Thirteen adult dogs diagnosed with anal sac gland carcinoma were enrolled in this prospective, pilot study, and ICTL was performed via peritumoral contrast injection with serial caudal abdominal computed tomography scans for iliosacral sentinel lymph node identification. Technical and descriptive details for ICTL were recorded, including patient positioning, total contrast injection volume, timing of contrast visualization, and sentinel lymph nodes and lymphatic pathways identified. Indirect CT lymphography identified lymphatic pathways and sentinel lymph nodes in 12/13 cases (92%). Identified sentinel lymph nodes were ipsilateral to the anal sac gland carcinoma in 8/12 and contralateral to the anal sac gland carcinoma in 4/12 cases. Sacral, internal iliac, and medial iliac lymph nodes were identified as sentinel lymph nodes, and patterns were widely variable. Patient positioning and timing of imaging may impact successful sentinel lymph node identification. Positioning in supported sternal recumbency is recommended. Results indicate that ICTL may be a feasible technique for sentinel lymph node identification in dogs with anal sac gland carcinoma and offer preliminary data to drive further investigation of iliosacral lymphatic metastatic patterns using ICTL and sentinel lymph node biopsy. © 2017 American College of Veterinary Radiology.

**Key words:** anal sac gland carcinoma, computed tomography, CT, dog, lymphatic, lymphography, sentinel lymph node.

## Introduction

**A**NAL SAC GLAND CARCINOMA IS A LOCALLY aggressive malignancy affecting geriatric dogs that exhibits high rates of locoregional lymphatic metastasis early in the course of disease.<sup>1-5</sup> At the time of diagnosis, a large proportion of dogs with anal sac gland carcinoma have documented metastatic lesions, with reported metastatic rates ranging from 36 to 96%.<sup>2-5</sup> Metastatic disease is most commonly noted regionally in the iliosacral lymphatic center, although distant lesions can develop in sites such as the liver, spleen, and lungs.<sup>2,5</sup> The presence of metastatic

disease is a negative prognostic indicator associated with shorter survival times, and documentation of metastasis impacts treatment recommendations.<sup>4,6,7</sup> Overall reported median survival times of dogs with anal sac gland carcinomas vary depending on the size of the primary tumor, the presence or absence of metastatic disease, and the type of therapy administered, and they range from 6 months to 3.5 years.<sup>4-8</sup> More recent studies document longer survival times, likely subsequent to advances in early disease detection and therapy.<sup>6,7</sup>

Current standard-of-care treatment recommendations include primary tumor resection and excision of grossly metastatic regional lymph nodes, with adjuvant chemotherapy and/or radiation therapy recommended for those cases with documented metastatic disease.<sup>4,5,8</sup> Several studies have shown that dogs are capable of long-term survival following surgical excision of local metastatic disease via lymphadenectomy, with survival times ranging from means of 1.7 to 3 years.<sup>6,9,10</sup> Given the relatively high

---

From the Veterinary Medical Teaching Hospital (Majeski, Fuller) and Department of Surgical and Radiological Sciences (Steffey, Hunt, Mayhew, Pollard), School of Veterinary Medicine, University of California-Davis, Davis, CA 95616.

This work was presented in part at the October 2016 annual meeting of the American College of Veterinary Surgery, Seattle, WA.

Address correspondence and reprint requests to Michele A. Steffey, at the above address. E-mail: masteffey@ucdavis.edu

Received October 18, 2016; accepted for publication December 7, 2016.

doi: 10.1111/vru.12482

---

*Vet Radiol Ultrasound, Vol. 00, No. 0, 2017, pp 1-9.*

rate of metastatic disease, its negative effect on survival, and the beneficial effects of surgical excision of lymphatic metastasis, detection of potential metastatic lesions is increasingly important, and accurate oncologic staging is essential. However, the impact of overt high-volume metastasis (visibly/ palpably enlarged and effaced lymph nodes) versus low-volume lymphatic metastasis (lymph nodes containing microscopic disease only without lymphadenomegaly) on prognosis and treatment recommendations is not well described.

Lymphatic drainage from the perineum classically travels first to the iliosacral lymphatic center, which includes the medial iliac lymph nodes, the internal iliac lymph nodes, and the sacral lymph nodes.<sup>11,12</sup> The medial iliac lymph nodes are single paired structures but can be double on either one or both sides which are typically located ventral to the 5th–6th lumbar vertebrae between the deep circumflex iliac and external iliac arteries within the retroperitoneal space. The internal iliac lymph nodes (previously known as the hypogastric nodes) are paired nodes found in the bifurcation of the internal iliac arteries and located ventral to the 6th–7th lumbar vertebrae.<sup>12</sup> The variably present sacral lymph nodes are located within the pelvic canal, ventral to the body of the sacrum, and typically lie on each side of the median sacral artery.<sup>12</sup>

Staging to evaluate the iliosacral lymph nodes for evidence of metastasis is important in dogs with anal sac gland carcinoma, and recent studies have shown that have shown that three-dimensional imaging such as magnetic resonance imaging (MRI) and contrast computed tomography (CT) are superior to ultrasound in the ability to identify iliosacral lymph nodes.<sup>13,14</sup> However, because of the complex anatomy of the iliosacral lymphatic center, in the absence of clear lymphadenomegaly it can be difficult to know which lymph nodes should be optimally prioritized if surgical or percutaneous sampling is desired. Additionally, the presence or absence of lymphadenomegaly does not necessarily denote the presence or absence of metastasis, and it is possible that sampling an inappropriate lymph node might give false-negative results. Sentinel lymph node mapping, widely utilized in the staging of a variety of human cancers,<sup>15–19</sup> identifies the lymph node most likely to contain tumor metastasis as a way to more accurately direct surgical staging in patients with complex lymphatic pathways and without overt lymphadenomegaly.<sup>15</sup> However, gold-standard methods of sentinel lymph node mapping used in people, such as lymphoscintigraphy, are not widely available to veterinarians. Indirect computed tomographic lymphography has been used successfully in both people and experimental animals for lymphatic and sentinel lymph node mapping.<sup>15,17,20–22</sup> As CT capability has become more readily available to veterinarians, the objective of this study was to evaluate the feasibility of an indirect CT lymphography technique as a possible method for

sentinel lymph node identification in a complex lymphocenter using a natural model of disease prone to lymphatic metastasis. Our hypothesis was that indirect CT lymphography using a commonly available, water-soluble iodinated contrast agent would prove to be a feasible method for iliosacral lymphatic mapping in a clinical cohort of dogs exhibiting naturally occurring anal sac gland carcinoma, and that tumoral lymphatic drainage in dogs with anal sac gland carcinoma would be variable between individuals.

## Materials and Methods

This prospective, pilot study was approved by and conducted in accordance with institutional guidelines established by the Clinical Trials Review Board for enrollment of client-owned animals in clinical trials. Client owned dogs that were presented to the University of California-Davis Veterinary Medical Teaching Hospital (UCD-VMTH) for surgical excision of anal sac gland carcinoma were enrolled between 2011–2014. Inclusion criteria for the study included a palpable mass in the region of the anal sac glands with a cytologic diagnosis of anal sac gland carcinoma and informed owner consent for indirect CT lymphography. Exclusion criteria included the presence of historical ipsilateral or contralateral anal sac gland carcinoma that received previous surgical excision and concurrent medical conditions that would preclude systemic administration of iodinated contrast as determined by the attending veterinary surgeon. Pre-CT diagnostics (either performed by the primary veterinarian or at the time of presentation to our practice) were performed as part of standard staging and pre-surgical work-up for anal sac gland carcinoma and included complete blood count, serum biochemistry panel, ionized calcium value, urinalysis, abdominal ultrasound, and thoracic radiographs.

Under general anesthesia, just prior to the scheduled surgical procedure, a precontrast CT (GE Medical Systems, Milwaukee, WI) study of the abdominal and pelvic cavities was performed with 2 mm collimation of the pelvic cavity and 5 mm collimation of the abdominal cavity. Subsequently indirect CT lymphography was performed via peritumoral injections (subcutaneous injection at the palpable tumor edge) of 1 ml of nonionic iodinated contrast material (Isovue 370<sup>®</sup>, 370 mg of I/ml; Bracco Diagnostics, Princeton, NJ) diluted 1:1 with sterile saline (for a total injection volume of 2 ml) in a four-quadrant technique (total dose volume divided and split among the quadrants). All injections were supervised by one of the authors (M.A.S.). Computed tomography of the pelvis and caudal abdomen was performed immediately prior to peritumoral contrast injection, as well as at 1, 3, 5, 10, and subsequently, if lymphatic contrast movement was slow or absent, up to 25 min after termination of the injection using a multislice helical scanner (GE Lightspeed, General Electric Co.,

Milwaukee, WI) using 2 mm slice thickness. Subsequent to obtaining indirect CT lymphography scans, intravenous contrast (Iovue 370<sup>®</sup>, 370 mg of I/ml; Bracco Diagnostics, Princeton, NJ) was injected at a dose of 740 mg kg<sup>-1</sup> into a cephalic or saphenous catheter, and the CT examination of the abdominal and pelvic cavities was repeated immediately after intravenous contrast injection to ensure optimal differentiation of lymph nodes from small regional vascular structures. Images were acquired in a standard algorithm. Precontrast images were obtained with kV = 120, the mAs = 200 and the pitch = 1.375:1. For indirect CT lymphography and post-IV contrast images, the kV = 120, the mAs = 150, and the pitch = 0.625:1.

Technical and descriptive details for indirect CT lymphography were recorded, including patient positioning, total contrast injection volume (if different from the planned 2 ml injection), timing of contrast visualization, and the lymphatic pathways and lymph nodes identified by peritumoral contrast injection. All data collection was performed by a single investigator (S.A.M.), who was blinded to any lymph node histopathology results at the time of initial review. A second unblinded review was performed by another observer (M.A.S.) and any discrepancies were resolved by consensus. Patient positioning methods included dorsal recumbency, standard sternal recumbency, and supported sternal recumbency, in which the patient was positioned with the sternum in contact with the CT table, and the pelvis was elevated and supported with a rolled-up towel in contact with the bony pubis such that there was no contact or pressure on the abdomen by the CT table, allowing the entirety of the abdominal wall to hang freely by gravity (Fig. 1). Lymphatic vessels with contrast uptake following peritumoral injection were followed visually from the injection site, and contrast uptake within lymph

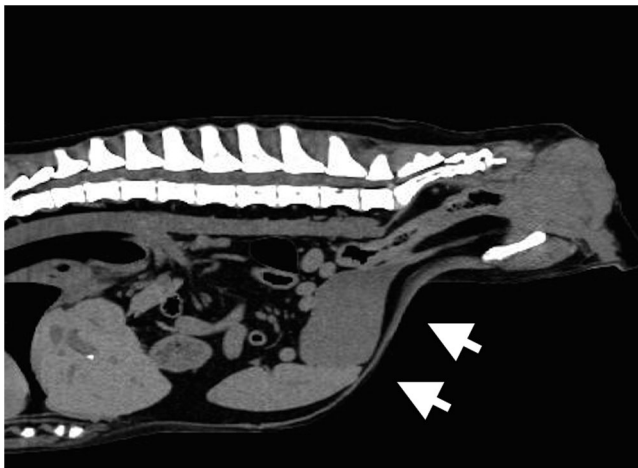


FIG. 1. Sagittal reformatted CT image of a dog in supported sternal body positioning. Note that the body wall and abdominal viscera sag ventrally due to gravity (white arrowheads), which minimizes pressure on dorsally located iliosacral lymphatic tracts.

nodes along each lymphatic pathway was identified and recorded. A primary, or first tier, sentinel lymph node was defined and identified as the first regional lymph node to uptake contrast material. If more than one lymphatic pathway was identified leading to separate contrast-enhancing lymph nodes, then each node was labeled as a primary sentinel lymph node. If a second lymph node along one lymphatic pathway was noted to be contrast enhancing, then this node was labeled as a second tier node, that is, a node receiving contrast via lymphatics connected to first tier sentinel nodes.

Measured lymph node size was recorded for all iliosacral lymph nodes identified on post-IV contrast CT scans by obtaining maximal diameters in all three dimensions by a single author (S.A.M.) blinded to histologic results at the time of data recording. Using previously reported normal mean lymph node cross-sectional diameters for iliosacral lymph nodes in normal dogs,<sup>23</sup> lymph nodes with a measured cross-sectional diameter in at least one dimension (width or height) of 8–10 mm were identified as mildly enlarged, those 11–19 mm identified as moderately enlarged, and those greater than 20 mm identified as markedly enlarged. Tumor volume was calculated using the equation for calculating volume of an ellipsoid ( $V = 4/3\pi * r1 * r2 * r3$ ) and also normalized to body weight.

## Results

A total of 13 dogs were enrolled in the study, nine males and four females, with a median age of 9.7 years (range, 4–12 years) and median body weight of 19.1 kg (range, 7.2–44 kg). Comparative data on the CT and ultrasonographic appearance of the iliosacral lymph nodes were previously reported in nine of the 13 dogs.<sup>13</sup> Six dogs had left-sided primary tumors; six dogs had right-sided tumors. One dog had both a left- and right-sided anal sac gland tumor; however, only the left-sided tumor received a peritumoral injection to avoid confusion in interpreting lymphatic contrast uptake. Primary tumor size ranged from 1.4 × 1.1 × 0.9 cm (5.8 cm<sup>3</sup>) to 9.5 × 7.8 × 6.7 cm (2080 cm<sup>3</sup>). Calculated tumor volume to patient body weight ranged from 0.2 to 73.3 cm<sup>3</sup>/kg. Seven dogs had one or more iliosacral lymph nodes identified as enlarged. Measured medial iliac lymph node sizes ranged from 0.8 × 0.4 × 0.4 to 2.4 × 1.2 × 0.8 cm. Measured internal iliac lymph node sizes ranged from <0.2 × 0.2 × 0.2 to 2.3 × 0.8 × 0.9 cm. Measured sacral lymph node size ranged from <0.2 × 0.2 × 0.2 to 0.9 × 0.8 × 0.5 cm. One dog with a proportionally large tumor had a large confluent lymphatic mass, and individual iliosacral lymph node sizes could not be determined. For the CT scans, dogs were placed in dorsal, standard sternal, and supported sternal positioning ( $n = 3, 3, \text{ and } 7$ , respectively). Positioning was not randomized; as a result of initial failures or prolonged delays in lymphatic

contrast uptake and flow during indirect CT lymphography imaging using dorsal or standard sternal positioning, supported sternal positioning was investigated. Four of the 13 dogs had a second peritumoral contrast injection administered identical to the first due to slow or absent uptake and movement of contrast within regional lymphatic more than 15 min after the initial injection. Persistence of peritumoral contrast material was visible throughout the duration of the repeated CT scans in all dogs. Individual patient signalment and sentinel lymph node mapping data are available in Appendices 1 and 2.

Indirect CT lymphography successfully identified lymphatic pathways and sentinel lymph nodes in 12/13 cases (92%) (Appendix 2). Variability was noted in the sentinel lymph nodes and lymphatic pathways identified. Sentinel lymph nodes were ipsilateral to the primary tumor in 8/12 cases (67%) and contralateral to the primary tumor in 4/12 cases (33%). The sentinel lymph node was identified as the medial iliac lymph node in 5/12 cases (42%) (Figs. 2 and 3), the internal iliac lymph node in 1/12 cases (8%), the sacral lymph node in 3/12 cases (25%), and a

combination of more than one sentinel lymph node by separate lymphatic pathways in 3/12 cases (25%) (Fig. 4). Where more than one sentinel lymph node was identified, both the medial iliac and sacral nodes were sentinel in two cases (16%), and both the medial iliac and internal iliac nodes were sentinel in one case (8%). Second tier lymph nodes were noted in 5/12 cases (42%) within the time imaging was performed. The time to initial sentinel lymph node identification after injection ranged from 1 to 20 min (median, 3 min). Time to sentinel lymph node identification postperitumoral injection (Appendix 2) was longer for dogs positioned in standard sternal recumbency ( $n = 3$ , times = 15, 15, and 20 min), and for dogs positioned in dorsal recumbency ( $n = 3$ , times = 3 and 13 min; one case never achieved successful indirect CT lymphography) compared to dogs positioned in supported sternal recumbency ( $n = 7$ , median time = 1 min (range, 1–13 min)). The case in which indirect CT lymphography was never achieved was also associated with a proportionally large primary mass lesion (calculated mass volume = 528 cm<sup>3</sup>, calculated mass volume/body weight = 73.3 cm<sup>3</sup>/kg). Two cases performed

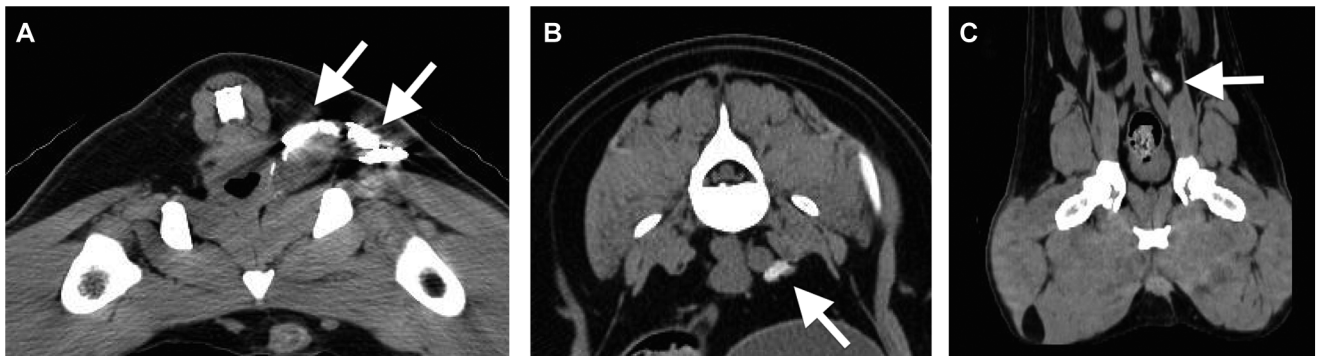


FIG. 2. Indirect CT lymphography case example; Window = 350, Level = 50. (A) Nonionic iodinated contrast material was injected peritumorally (white arrows) and is visible on the CT image. (B) Transverse CT image of the medial iliac lymph node that is contrast enhancing at 1 min (white arrow). (C) A multiplanar reconstruction of the CT image showing medial iliac lymph node contrast uptake (white arrow).

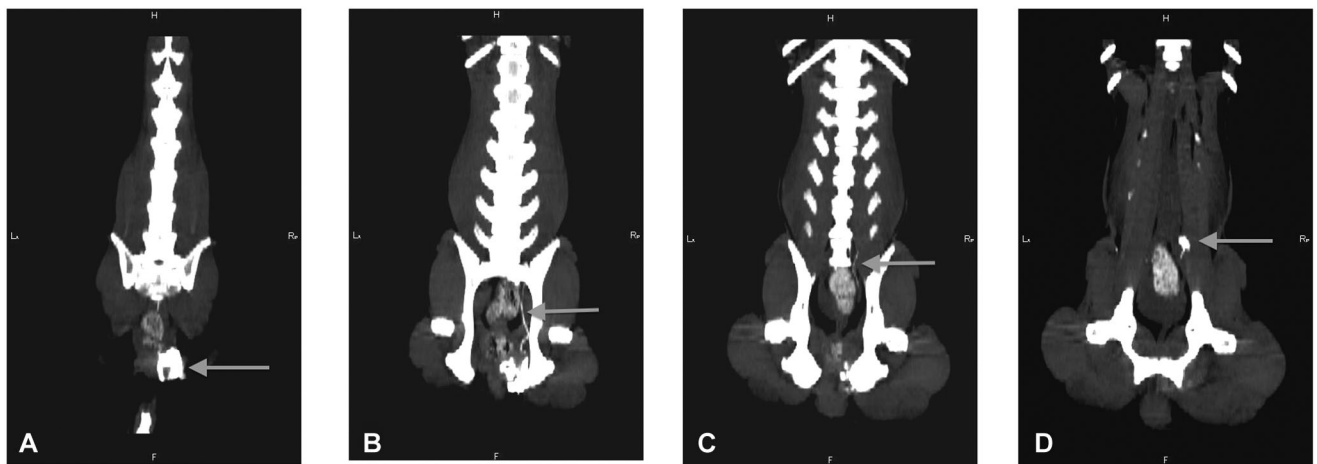


FIG. 3. (A–D) Dorsal multiplanar reconstructions of a CT scan (Window = 350, Level = 90) illustrating lymphatic flow of contrast (white arrows) from a peritumoral injection around the primary tumor (A) and traveling cranially through the pelvis to the medial iliac node (D).

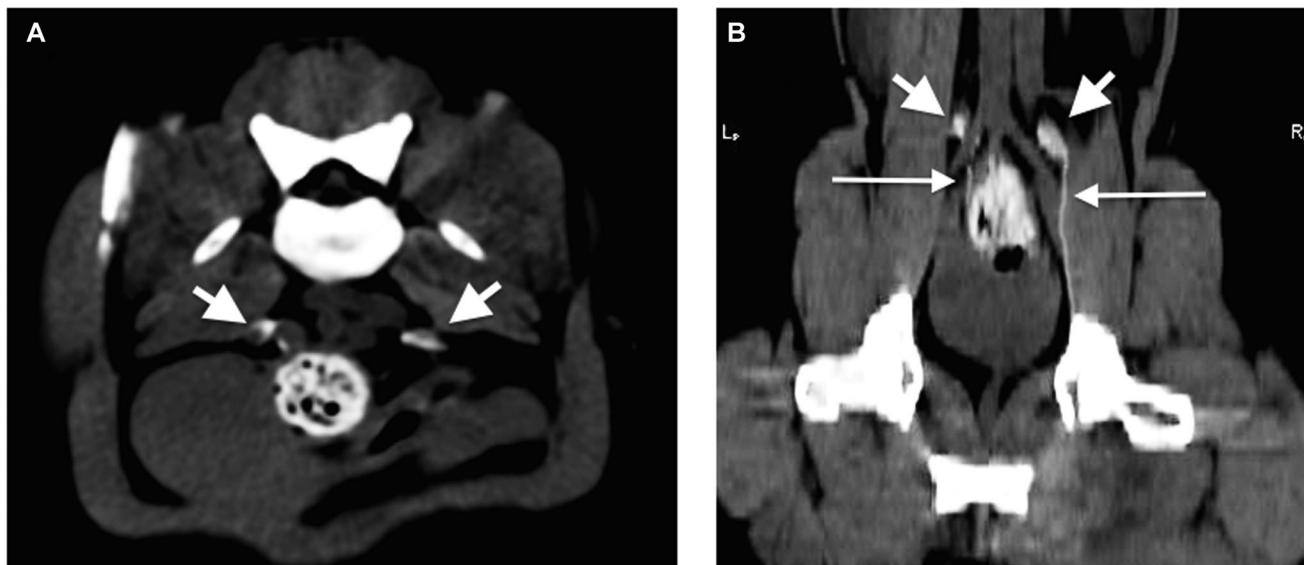

FIG. 4. Transverse (A) and dorsal multiplanar (B) reconstruction views of a CT scan (Window = 350, Level = 90) demonstrating two separate lymphatic pathways (thin white arrows) leading to both left and right medial iliac lymph nodes (large white arrowheads).

in the supported sternal position that initially had delayed contrast movement, but rapid lymphatic uptake of contrast after injection of additional contrast volume were associated with proportionally large primary mass lesions.

### Discussion

This pilot study was performed to generate preliminary data in order to define a protocol for the use of indirect CT lymphography for sentinel lymph node mapping in dogs with anal sac gland carcinoma. Indirect CT lymphography using peritumorally administered iopamidol proved to be a feasible method for iliosacral lymphatic mapping. Indirect CT lymphography was technically successful in identification of at least one sentinel lymph node in the majority of cases (92%), and study results documented wide interindividual variability in the lymphatic pathways and location of sentinel lymph nodes identified in the iliosacral lymphatic center. Additionally, technical considerations that may contribute to the success or failure of the imaging study, including patient positioning, timing of imaging, total injection volume, and primary mass size, were identified.

Although indirect CT lymphography has been previously described for peripheral mammary lymphatic mapping in cats,<sup>20,21</sup> this study investigated a technique for lymphatic mapping of a complex internal lymphocenter in clinically affected dogs. In this small cohort of dogs, it appeared that patient positioning at the time of indirect CT lymphography may strongly impact the timing of sentinel lymph node identification in the iliosacral lymphatic center. Pressure on the lymphatic system has been documented to negatively

affect lymphatic drainage.<sup>24</sup> Sternal positioning combined with pelvic support was adopted to minimize abdominal pressure, and this yielded quicker times to sentinel lymph node identification than standard sternal or dorsal body positions with consistent lymphatic identification 1–3 min postinjection. Despite the low numbers, and confounding factors of mass and lymph node size in individual patients, rapid and successful indirect CT lymphography was consistently achieved with supported sternal positioning, even in cases with proportionally large tumor burdens. Indirect CT lymphography success may be achieved in other positions, but supported sternal positioning produced the most rapid and consistent imaging studies. Other technical considerations in defining the indirect CT lymphography protocol for this cohort were based on previous work documented in sentinel lymph node mapping in people and animals, including subcutaneous peritumoral rather than intratumoral injections,<sup>25</sup> the volume of contrast injected,<sup>26</sup> and postinjection massage for increased sentinel lymph node dye uptake.<sup>27</sup>

Lymphatic variability is documented in both people and dogs.<sup>13,15–17,20</sup> The medial iliac lymph node was most commonly identified as a sentinel lymph node for anal sac gland carcinoma in our study (eight of 15 lymph nodes, 53%), followed by the sacral lymph node (5/15, 33%) and the internal iliac lymph node (2/15, 13%). Interestingly, 25% of cases had multiple sentinel lymph nodes identified, in which two separate lymphatic pathways appeared to drain the primary tumor. However, several factors in this small and uncontrolled cohort may have affected the lymphatic drainage, and the precise lymph node identified as sentinel. Therefore, the specific rates of involvement

for each individual lymph node (sacral, internal iliac, or medial iliac) should be interpreted with caution. Many of the dogs in our study population had proportionally large tumors, and several of the dogs had lymphadenomegaly of at least one iliosacral node. While we were not aware of these considerations during study recruitment, disease levels including large primary tumors and lymphadenomegaly likely secondary to overt metastatic lymphatic disease burden, have been shown to negatively impact accurate sentinel lymph node identification and/or lead to false identification of an incorrect sentinel lymph node (and therefore a false negative stage patient with regards to identification of metastatic disease), likely due to altered lymphatic routes subsequent to infiltrative disease.<sup>26,28-34</sup> The one case in our cohort in which a successful indirect CT lymphography study could not be obtained had a proportionately very large primary tumor, which may have impacted the ability to achieve a successful indirect CT lymphography study. Primary tumor size is also likely to have impacted the required injection volume or timing in two dogs in the supported sternal positioning group, in which the lymphatic uptake of contrast was delayed after the first injection, but which progressed rapidly after injection of a second dose of contrast. With respect to existing lymphadenomegaly, it is suggested that with existing regional lymph node enlargement, lymphatic flow rates and/or directions may be altered by the presence of gross lymphatic metastasis, and while a recorded lymph node may be identified as “sentinel” by the imaging study, it may in fact be falsely identified and not representative of the most likely lymph node to contain metastasis.<sup>33</sup> In the 7/13 dogs that were identified as having lymphadenomegaly, lymph node enlargement was classified as “mild” in 5/7 dogs, moderate in 1/7 dogs, and severe in 1/7 dogs. There is no clear empirical cutoff for how much lymphadenomegaly is “too much” lymphadenomegaly when performing sentinel lymph node mapping, but clinicians should be aware of this potential impact when applying this technique. Sentinel lymph node mapping is ideally applied to identify which node to sample when assessing for low volume metastatic disease, and a prospective study of sentinel lymph node mapping is needed limited to dogs with anal sac gland carcinoma but without gross lymphadenomegaly. This would also help to elucidate rates and prognostic implications of micrometastasis of anal sac gland carcinoma, which are not yet well defined. It is unknown whether the specific sentinel lymph nodes and lymphatic pathways we identified in our study were affected by the relatively large tumor burden (i.e., large primary tumors and regional lymphadenomegaly) of our case population.

While the impacts of bulky lymphatic metastasis on prognosis in dogs with anal sac gland carcinoma are clearly documented, what is not currently well understood is the impact of low-volume lymphatic metastasis on prognosis and therapeutic recommendations for this disease, making

it difficult to make informed direct clinical recommendations for iliosacral lymphatic biopsy. However, in the long run, these impacts can only be understood if we are correctly staging patients and accurately stratifying outcomes according to level of disease, and correct staging requires accurate identification and sampling of the correct lymph node(s) when reporting rates of lymphatic metastasis.<sup>35</sup> While ultrasound-guided aspiration is a viable staging option, and laparoscopic approaches to the medial iliac lymph node have been described for lymph node sampling,<sup>36</sup> there exists a need to ensure that correct nodal sampling is occurring in a complex lymphocenter such as the iliosacral site. Sentinel lymph node mapping is a means of doing so. Impacts of low volume metastatic disease on prognosis and treatment recommendations have been clearly documented in other types of carcinomas in people.<sup>37,38</sup> While the specific lymph nodes identified as sentinel in this study should be interpreted with caution, as many of the dogs had proportionately large tumors and several had lymphadenomegaly, this study offers further proof of lymphatic pathway variability in a natural tumor model, and documents that indirect CT lymphography, as a method of sentinel lymph node mapping, has the potential to be useful in the preoperative determination of which lymph nodes to evaluate for potential metastatic disease.

Study limitations include low patient numbers and unanticipated technical challenges in implementing a new technique. Patient positioning for the CT scans evolved during study enrollment, adapting to the delays and failures of initial cases, and so there is a lack of randomization and unequal group sizes for the body positions used in this study. The volume of contrast injected relative to tumor size can affect the success of sentinel lymph node identification,<sup>26</sup> and it is unknown whether some of the larger tumors in this study might have required a higher contrast volume for more rapid successful mapping. Additionally, our patient population was not controlled for primary tumor size and lymphadenomegaly. As previously stated, future sentinel lymph node mapping studies should ideally be controlled to optimize the identification of low volume metastatic disease, i.e. with exclusion of patients with overt lymphadenomegaly in order to minimize the risk of false positive identification of sentinel lymph nodes. Moreover, while the ability to visually follow contrast uptake through lymphatic pathways directly from the peritumoral injection site to the identified sentinel lymph node without surgical disruption of tissue provides increased confidence in the identification of sentinel lymph nodes with this technique, this indirect CT lymphography technique was not compared to currently recommended methods of sentinel lymph node identification such as scintigraphy or optical dye administration, and a comparative study of techniques would be beneficial. In a recent multicenter study in humans, three-dimensional single-photon emission CT (SPECT/CT) detected more

sentinel lymph nodes than planar scintigraphic imaging, demonstrating the benefit of three-dimensional imaging in complex anatomical areas.<sup>39</sup> Lastly, as this study was performed in client-owned dogs and was designed to generate pilot data on technique feasibility and technical considerations, there is a lack of data on the actual incidence of lymphatic metastasis associated with the sentinel lymph node identified.

In conclusion, this study demonstrated that indirect CT lymphography offers a feasible method of preoperative sentinel lymph node identification in the iliosacral lymphatic center in dogs. Minimizing pressure on the lymphatic system with proper patient positioning affects the success and timing of indirect CT lymphography studies. In the application of indirect CT lymphography for sentinel lymph node mapping studies, veterinarians should consider the impacts of patient selection (i.e. factors such as primary tumor size and the absence of existing major lymphadenomegaly) in order to maximize the likelihood of accurate sentinel lymph node identification. Based on findings from the current study, authors recommend that an indirect CT lymphography protocol for the iliosacral lymphatic center be performed with the dog in a supported sternal recumbency with minimal abdominal pressure and with peritumoral injection of diluted iodinated contrast material in a four-quadrant technique. We also recommend obtaining images starting at 1 min following peritumoral injection and repeating as needed until contrast uptake is identified in the first lymph node(s). Repeated peritumoral injection is

recommended if lymphatic contrast uptake is not observed by 5 min postinjection. Advancements in our understanding of iliosacral lymphatic metastasis are likely to offer opportunities to improve staging accuracy and to optimize treatment recommendations in canine patients diagnosed with anal sac gland carcinoma, and further investigation of iliosacral lymphatic metastatic patterns using indirect CT lymphography is warranted.

#### LIST OF AUTHOR CONTRIBUTIONS

##### Category 1

- (a) Conception and Design: M. A. Steffey
- (b) Acquisition of Data: M. A. Steffey, R. E. Pollard, S. A. Majeski, M. Fuller, P. D. Mayhew, G. B. Hunt
- (c) Analysis and Interpretation of Data: M. A. Steffey, S. A. Majeski, R. E. Pollard

##### Category 2

- (a) Drafting the Article: S. A. Majeski, M. A. Steffey
- (b) Revising Article for Intellectual Content: R. E. Pollard, M. Fuller, P. D. Mayhew, G. B. Hunt

##### Category 3

- (a) Final Approval of the Completed Article: S. A. Majeski, M. A. Steffey, R. E. Pollard, M. Fuller, P. D. Mayhew, G. B. Hunt

#### ACKNOWLEDGMENTS

This project was supported by funding from the University of California-Davis Center for Companion Animal Health.

### Appendix 1: Patient Body Weight, Primary Tumor, and Iliosacral Lymphocenter Data for the 13 Sampled Dogs

Case	Body weight (kg)	Primary tumor dimensions (cm)	Calculated tumor volume (cm <sup>3</sup> )	Calculated tumor volume to body weight (cm <sup>3</sup> /kg)	Lymphadenomegaly on CT Scan	Number of enlarged nodes	Degree of lymphadenomegaly	Largest node cross-sectional diameter (cm)*
1	31	1.4 × 1.1 × 0.9	5.8	0.2	Yes	1	Moderate	1.1
2	15.6	2.3 × 1.5 × 1.9	27.5	1.8	No	–	–	–
3	14.2	1.4 × 0.9 × 1.3	6.9	0.5	No	–	–	–
4	14.3	2.0 × 1.3 × 1.9	20.7	1.4	Yes	2	Mild	0.9
5	43.8	3.4 × 2.0 × 3.2	91.2	2.1	No	–	–	–
6	19.1	2.1 × 0.6 × 1.0	5.3	0.3	No	–	–	–
7	44	9.5 × 7.8 × 6.7	2080	47.3	No	–	–	–
8	7.4	1.7 × 1.3 × 1.5	13.9	1.9	No	–	–	–
9	8.2	2.3 × 2.0 × 2.1	40.5	4.9	Yes	1	Mild	0.8
10	29	3.7 × 2.1 × 2.4	78.1	2.7	Yes	1	Mild	0.8
11	21.1	7.0 × 6.0 × 5.5	968	45.9	Yes	1	Mild	0.8
12	36	7.0 × 5.0 × 7.5	1100	30.5	Yes	1	Mild	1.0
13	7.2	9.0 × 4.0 × 3.5	528	73.3	Yes	5	Marked	N/A**

\*Width and height evaluated as parameters for measured lymphadenomegaly.

\*\*Case 13 had one large confluent lymphatic mass consisting of the majority of the iliosacral lymphocenter and therefore no individual node measurements were obtained.

CT, computed tomography.

## Appendix 2: Summary of Indirect Computed Tomography (CT) Lymphography and Sentinel Lymph Node Mapping Data

Case	CT scan positioning	Number of peritumoral injections	Total injection volume (ml)	Time for SLN identification (min)	SLN(s) identified	SLN side relative to tumor	Second tier nodes identified
1	Standard sternal	1	2	15	Sacral	Ipsilateral	Yes
2	Standard sternal	2	4	15*	Sacral	Ipsilateral	No
3	Standard sternal	1	2	20	Medial iliac	Ipsilateral	Yes
4	Dorsal	2	4	3*	Medial iliac	Contralateral	No
5	Dorsal	1	2	13	Medial iliac	Ipsilateral	No
6	Supported sternal	1	2	3	Sacral	Ipsilateral	Yes
7	Dorsal	1	2	N/A**	N/A**	N/A**	No
8	Supported sternal	1	2	3	Medial iliac, Sacral	Contralateral	Yes
9	Supported sternal	1	2	1	Medial iliac, Internal iliac	Ipsilateral	Yes
10	Supported sternal	1	2	1	Medial iliac, Sacral	Contralateral	Yes
11	Supported sternal	2	4	1*	Internal iliac	Ipsilateral	Yes
12	Supported sternal	2	4	1*	Medial iliac	Ipsilateral	No
13	Supported sternal	1	2	3	Medial iliac	Contralateral	No

\*SLN, sentinel lymph node. Due to delayed contrast uptake or lack of SLN identification by 10 min postinjection, a second injection with a subsequent 2 ml of 1:1 diluted contrast was performed. Time for SLN identification for these cases is the time after the second injection.

\*\*ICTL, indirect computed tomographic lymphography. This method was not successful for case 7.

### REFERENCES

- Berrocal A, Vos JH, van den Ingh TS, et al. Canine perineal tumors. *J Vet Med Ser A* 1989;36:739–749.
- Goldschmidt MH, Zoltowski C. Anal sac adenocarcinoma in the dog: 14 cases. *J Small Anim Pract* 1981;22:119–128.
- Meuten DJ, Cooper BJ, Capen CC, et al. Hypercalcemia associated with an adenocarcinoma derived from the apocrine glands of the anal sac. *Vet Pathol* 1981;18:454–471.
- Ross JT, Scavelli TD, Matthesen DT, et al. Adenocarcinoma of the apocrine glands of the anal sac in dogs: a review of 32 cases. *J Am Anim Hosp Assoc* 1991;27:349–355.
- Bennett PF, DeNicola DB, Bonney P, et al. Canine anal sac adenocarcinomas: clinical presentation and response to therapy. *J Vet Intern Med* 2002;16:100–104.
- Polton GA, Brearley MJ. Clinical stage, therapy, and prognosis in canine anal sac gland carcinoma. *J Vet Intern Med* 2007;21:274–280.
- Potanas CP, Padgett S, Gambin RM. Surgical excision of anal sac apocrine gland adenocarcinomas with and without adjunctive chemotherapy in dogs: 42 cases (2005–2011). *J Am Vet Med Assoc* 2015;246:877–884.
- Williams LE, Gliatto JM, Dodge RK, et al. Carcinoma of the apocrine glands of the anal sac in dogs: 113 cases (1985–1995). *J Am Vet Med Assoc* 2003;223:825–831.
- Jeffery N, Phillips SM, Rearley MJ. Surgical management of metastases from anal sac apocrine gland adenocarcinoma of dogs. *J Small Anim Pract* 2000;41:390.
- Hobson HP, Brown MR, Rogers KS. Surgery of metastatic anal sac adenocarcinoma in five dogs. *Vet Surg* 2006;35:267–270.
- Llabré s-Díaz FJ. Ultrasonography of the medial iliac lymph nodes in the dog. *Vet Radiol Ultrasound* 2004;45:156–165.
- Bezuidenhout AJ. The lymphatic system. In: Evans HE (ed): *Miller's anatomy of the dog*. Philadelphia: Saunders, 1993;741–745.
- Pollard RE, Fuller MC, Steffy MA. Ultrasound and computed tomography of the iliosacral lymphatic centre in dogs with anal sac gland carcinoma. *Vet Comp Oncol* 2015;doi:10.1111/vco.12160
- Anderson CL, MackKay CS, Roberts GD, et al. Comparison of abdominal ultrasound and magnetic resonance imaging for detection of abdominal lymphadenopathy in dogs with metastatic apocrine gland adenocarcinoma of the anal sac. *Vet Comp Oncol* 2015;13:98–105.
- Tangoku A, Yamamoto S, Suga K, et al. Sentinel lymph node biopsy using computed tomography-lymphography in patients with breast cancer. *Surgery* 2004;135:258–265.
- Morton DL, Wen DR, Wong JH, et al. Technical details of intraoperative lymphatic mapping for early stage melanoma. *Arch Surg* 1992;127:392–399.
- Shu Y, Xu X, Chodara AM, et al. Correlative study of indirect computed tomography lymphograph using iopamidol and histopathology in a cervical lymph node metastasis model. *Laryngoscope* 2011;121:724–731.
- Yuasa Y, Seike J, Yoshida T, et al. Sentinel lymph node biopsy using intraoperative indocyanine green fluorescence imaging navigated with preoperative CT lymphography for superficial esophageal cancer. *Ann Surg Oncol* 2012;19:486–493.
- Van der Vorst JR, Schaafsma BE, Verbeek FPR, et al. Randomized comparison of near-infrared fluorescence imaging using indocyanine green and 99m technetium with or without patent blue for the sentinel lymph node procedure in breast cancer patients. *Ann Surg Oncol* 2012;19:4104–4111.
- Patsikas MN, Papadopoulou PL, Charitanti A, et al. Computed tomography and radiographic indirect lymphography for visualization of mammary lymphatic vessels and the sentinel lymph node in normal cats. *Vet Radiol Ultrasound* 2010;51:299–304.
- Papadopoulou PL, Patsikas MN, Charitanti A. The lymph drainage pattern of the mammary glands in the cat: a lymphographic and computerized tomography lymphographic study. *Anat Histol Embryol* 2009;38:292–299.
- Suga K, Yuan Y, Ueda K, et al. Computed tomography lymphography with intrapulmonary injection of iopamidol for sentinel lymph node localization. *Invest Radiol* 2004;39:313–324.
- Beukers M, Grosso FV, Voorhout G. Computed tomographic characteristics of presumed normal canine abdominal lymph nodes. *Vet Radiol Ultrasound* 2013;54:610–617.
- Guyton AC. Interstitial fluid pressure. II. Pressure-volume curves of interstitial space. *Circ Res* 1965;16:452–460.
- Wisner ER, Seibert JA, Katzberg RW. Quantitative methods for indirect CT lymphography. *Vet Radiol Ultrasound* 1998;39:110–116.
- Viehl CT, Hamel CT, Marti WR, et al. Identification of sentinel lymph nodes in colon cancer depends on the amount of dye injected relative to tumor size. *World J Surg* 2003;27:1285–1290.
- Bass SS, Cox CE, Salud CJ, et al. The effects of postinjection massage on the sensitivity of lymphatic mapping in breast cancer. *J Am Coll Surg* 2001;192:9–16.
- Sommariva A, Donisi PM, Gnocolo B, et al. Factors affecting false-negative rates on ex vivo sentinel lymph node mapping in colorectal cancer. *Eur J Surg Oncol* 2010;36:130–134.



29. Wong SL, Edwards MJ, Chao C, et al. The effect of lymphatic tumor burden on sentinel lymph node biopsy results. *Breast J* 2002;8:192–198.
30. Wong SL, Edwards MJ, Chao C, et al. Sentinel lymph node biopsy for breast cancer: impact of the number of sentinel nodes removed on the false-negative rate. *J Am Coll Surg* 2001; 192:684–689.
31. Sener SF, Winchester DJ, Brinkmann E, et al. Failure of sentinel lymph node mapping in patients with breast cancer. *J Am Coll Surg* 2004;198:732–736.
32. Schlag PM, Bembenek A. Specification of potential indications and contraindications of sentinel lymph node biopsy in breast cancer. *Recent Results Cancer Res* 2000;157:228–236.
33. Goyal A, Douglas-Jones AG, Newcombe RG et al. Effect of lymphatic tumor burden on sentinel lymph node biopsy in breast cancer. *Breast J* 2005;11:188–194.
34. Quadros CA, Lopes A, Araujo I, et al. Upstaging benefits and accuracy of sentinel lymph node mapping in colorectal adenocarcinoma nodal staging. *J Surg Oncol* 2008;98:324–330.
35. Webster JD, Dennis MM, Dervisis N, et al. Recommended guidelines for the conduct and evaluation of prognostic studies in veterinary oncology. *Vet Pathol* 2011;48:7–18.
36. Steffey MA, Daniel L, Mayhew PD, et al. Laparoscopic extirpation of the medial iliac lymph nodes in normal dogs. *Vet Surg* 2015;44:59–65.
37. Cox CE, Kiluk JV, Riker AI, et al. Significance of sentinel lymph node micrometastases in human breast cancer. *J Am Coll Surg* 2009;206:261–268.
38. Rusch VW, Hawes D, Decker PA, et al. Occult metastases in lymph nodes predict survival in resectable non-small-cell lung cancer: report of the ACOSOG Z0040 trial. *J Clin Oncol* 2011;29:4313–4319.
39. Jimenez-Heffernan A, Ellmann A, Sado H, et al. Results of a prospective multicenter international atomic energy agency sentinel node trial on the value of SPECT/CT over planar imaging in various malignancies. *J Nucl Med* 2015;56:1338–1344.